



Ciprian OBER, Phd, Associate Professor, Resident of
European College of Veterinary Surgeons
Department of Surgery
Faculty of Veterinary Medicine Cluj-Napoca
Phone: 0040749262180
Email: ciprian.ober@usamvcluj.ro

Owner: Raluca

Patient: 11y spayed female dog cross breed

Surgeon: Ciprian OBER, DVM, PhD, ResECVS

Anamnesis: previous diagnosis of mammary carcinoma.

Physical exam: good general condition; pelvic region wobbling

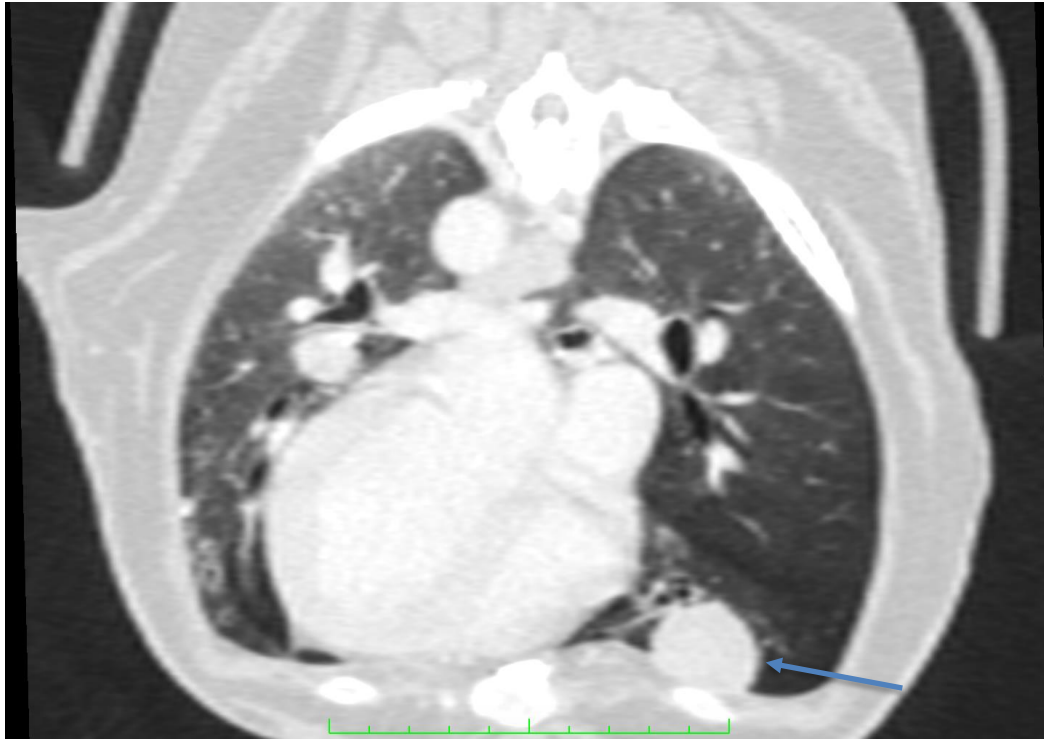
Complementary exams: CT scan

see images and interpretation

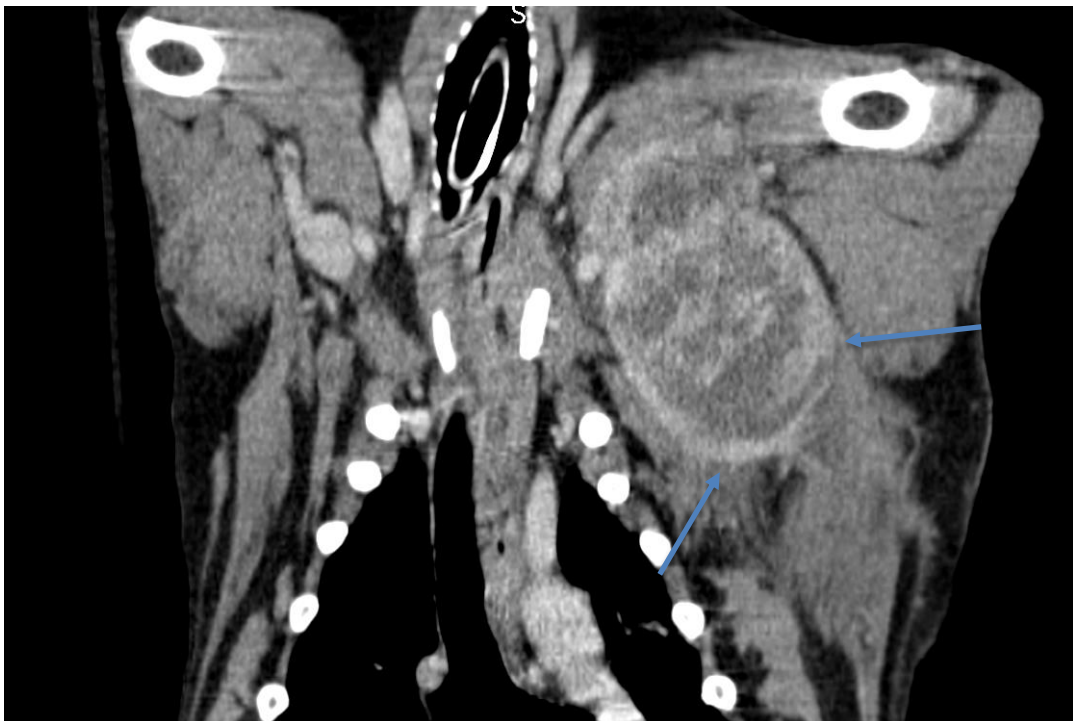Diagnosis: most probably widespread pulmonary metastasis of mammary adenocarcinoma.

Treatment

Cytology and biopsy of the left axillary region swelling



Multiple soft-tissue attenuating pulmonary nodules ranging from 1–15 mm in diameter are distributed throughout all lung lobes. There is a focal region in the ventral aspect of the right hemithorax, in which nodules appear to coalesce (arrowhead). Medial tracheobronchial lymph node is also enlarged



Fluid filled, heterogeneous contrast enhancement well delineated round swelling at the level of the left axilla (arrows); cytology, evacuation and capsule biopsy were performed for definitive diagnosis